
CASE REPORT

Phaeochromocytoma combined with subclinical Cushing's syndrome and pituitary microadenoma

Guzin Fidan Yaylali, MD¹

Fulya Akin, MD¹

Mehmet Bastemir, MD¹

Yalın Tolga Yaylali²

Akin Ozden, MD³

¹Pamukkale University, School of Medicine
Department of Endocrinology and Metabolic Dis-
eases, Denizli, Turkey

²Servergazi State Hospital Department of Cardiology,
Denizli, Turkey

³Pamukkale University, School of Medicine
Department of Surgery, Denizli, Turkey

Manuscript submitted 8th February, 2008

Manuscript accepted 28th April, 2008

Clin Invest Med 2008; 31 (3): E176-E181.

Abstract

Objectives: Phaeochromocytoma (PHEO) occasionally associates with pathological lesions of the adrenal cortex. The coexistence of PHEO and pre-clinical Cushing's syndrome (PCS) of the same adrenal gland has rarely been reported. We report a case of PHEO and PCS originating from the same adrenal gland and discuss the peculiar diagnostic aspects of this entity.

Clinical Presentation: A 64 yr old man was hospitalized to evaluate the right adrenal mass which was discovered incidentally by ultrasonography. He had a history of type 2 diabetes mellitus and hyperlipidemia. Blood pressure measurements were all normal during his hospital stay. Laboratory examination showed: urinary catecholamines were markedly increased. HbA1C of 14.3 %, midnight cortisol of 11(µg/dL), cortisol was not suppressed after the overnight 1 mg oral dexamethasone suppression test (DST): 3.42(µg/dL), 24 hr free cortisol in the urine : 213 µg/day (10-100), cortisol levels were suppressed more than 50% with 8 mg of dexamethasone. CT scan of the adrenal glands showed a 6 cm well encapsulated right adrenal mass together with a clearly normal left adrenal gland. MRI investigation of the sella turcica revealed a pituitary microadenoma on the right side of the adenohypophysis. He was treated with α and subsequent β blockers after the

diagnosis of PHEO and PCS was made. Right adrenalectomy was performed. The pathology showed typical PHEO with adrenocortical hyperplasia. VMA, metanefrin and free cortisol levels were normalized one month after surgery.

Conclusion: The present report is a rare case of PHEO combined with PCS in the same adrenal gland.

Hypercortisolism in patients with tumours of the autonomic nervous system has been reported previously. Luton *et al.* reviewed cases with pheochromocytoma and hypercortisolism due to adrenal tumours.¹ Other combinations include the production of steroid hormones by a tumour of the autonomic nervous system, concomitant adreno-cortical and -medullary tumours, ectopic production of corticotropin releasing factor (CRF), and multiple endocrine neoplasia.^{2,3} In most of cases of phaeochromocytoma (PHEO) associated with Cushing's syndrome (CS), ectopic adrenocorticotrophic hormone (ACTH) produced by PHEO resulted in bilateral adrenocortical hyperplasia.^{4,5} Coexistence of PHEO and non-ACTH dependent CS is very rare.^{6,7}

TABLE 1. Baseline laboratory parameters.

Biochemical parameters (plasma)		Hormone levels (normal values)			
Fasting blood glucose (mg/dL)	335	DHEA-S (µg/dL)	36 (35-430)	Midnight cortisol (µg/dL)	11
Total cholesterol(mg/dL)	290	ACTH (pg/ml)	18.1 (0-46)	1 mg dex suppression (µg/dL)	3.42
Triglyceride (mg/dL)	209	Cortisol (µg/dL)	18.2 (5-25)	24 hour free cortisol in the urine (µg/d)	213 (10-100)
LDL Cholesterol(mg/dL)	164	FSH (mIU/mL)	3.84 (1.5-12.4)	8 mg dex suppression (µg/dL)	2.13
AST (IU/L)	16	LH (mIU/mL)	4.27 (1.7-8.6)	Renin (ng/ml/h)	5.6 (0.2-3.4)
ALT (IU/L)	36	Testosterone (ng/dl)	235 (181-758)	Aldosterone (pg/ml)	115 (20-240 pg/ml)
BUN (mg/dL)	17	IGF-1 (ng/mL)	53.3 (71-290)	Normetanefrin (µg/d)	1706 (88-444)
Creatinine (mg/dL)	0.79	TSH (mIU/mL)	0.9 (0.7-4.2)	VMA (mg/d)	138 (3-9)
Na (mmol/L)	133	Ft4 (ng/dl)	1.13	metanefrin (µg/d)	> 2000 (52-341)
K (mmol/L)	4.5	PTH (pg/mL)	78.8 (11-67)		
Calcium (mmol/L)	9.4	Vit D (ng/mL)	<7		
Phosphorus(mmol/L)	3.8	HbA1C	14.3		

ACTH: adrenocorticotropic hormone

AST: aspartate aminotransferase

ALT: alanine aminotransferase

BUN: blood urea nitrogen

DHEA-S: dehydroepiandrosterone sulphate

FSH: follicle stimulating hormone

Ft4: free thyroxine

IGF-1: insulin like growth factor

LH : luteinizing hormone

PTH: parathyroid hormone

TSH: thyroid stimulating hormone

Cortisol secreting cortical adenomas present clinically as CS, but may also be silent, exhibiting only lack of dexamethazone suppression and occasionally increased urinary cortisol excretion, the so called pre-clinical or subclinical CS. (PCS).⁸ The prevalence of PCS discovered from adrenal incidentalomas has varied from 6-20%, because of various diagnostic criteria and the small number of cases to be examined statistically.

We report a case of PHEO and PCS originating from the same adrenal gland which is extremely rare.

Clinical Presentation

A 64 yr old man was hospitalized to evaluate the right adrenal mass which was incidentally discovered by abdominal ultrasonography. He was 170 cm tall, 72 kg weight, and 25kg/m² body mass index. He had a history of type 2 diabetes mellitus and hyperlipidemia. He complained of occasional sweating and weight loss of 10 kg over the last 5 months. He was taking repaglinide 3 mg tid and metformin 850 mg bid prior to admission. Treatment was switched to intensive in-

sulin treatment due to his HbA1C of 14.3%. His c-peptide level was 1.77 and fasting insulin:26.5 at that time showing insulin resistance. Blood sugar concentration was controlled with 150 units of insulin per day.

Physical examination was unremarkable on admission. Blood pressure measurements during hospital stay and blood pressure Holter monitoring were all normal. Laboratory results shown in table 1. Cardiac work up was normal including normal echocardiography and negative exercise stress test. There was no diabetic retinopathy.

CT scan of the adrenal glands showed a 6 cm well encapsulated right adrenal mass together with a clearly normal left adrenal gland (figure 1). MRI investigation of the sella turcica revealed a pituitary microadenoma (4mm in diameter) on the right side of the adenohypophysis (figure 2).

He was treated with α and subsequent β blockers after the diagnosis of PHEO and PCS was made. After 1 week of α blocker (doxazosin 4mg bid) therapy he received 2 weeks of β blocker (carvedilol 12.5 mg bid) before surgery (figure 3). He received 2000ml

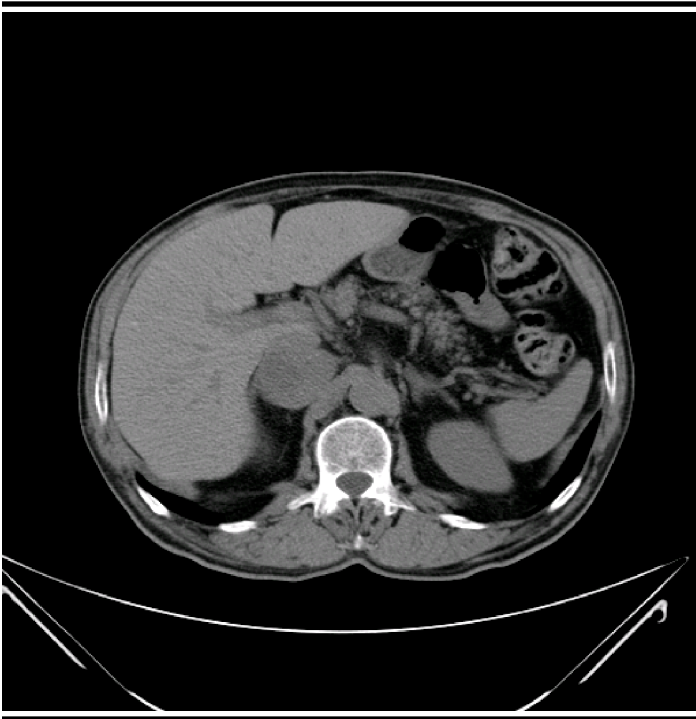


FIGURE 1. Computed tomographic scan of abdomen showing a 6 cm well encapsulated mass of right adrenal mass together with a clearly normal left adrenal gland.

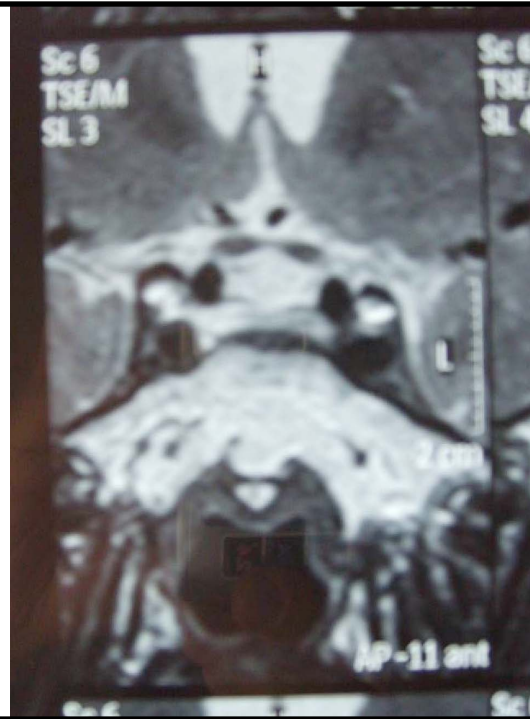


FIGURE 2. MRI scan of hypophysis showing a 4mm microadenoma on the right side of the adenohypophysis.

saline infusion per day for one week preoperatively. We looked for other MEN2a components before the surgery but neither of them existed. Osteomalacia was diagnosed, based on normal calcium levels, PTH at the upper limit of normal and very low vitamin D levels and he was given vit D. As he had PCS, methylprednisolone (40 mg per day) was commenced on the day before surgery and tapered off gradually over 2 weeks. He also received intensive insulin treatment of 200 IU/ day. The pathology showed typical PHEO with positive immunostaining for chromogranine A, synaptophysin and adrenocortical hyperplasia. There was no information about ACTH immunohistochemistry in tumour tissue. There were no hypotensive/hypertensive and /or hypoglycemia attacks during or after surgery.

Insulin was tapered and he was discharged on metformin 1000 mg bid, rosiglitazone 4 mg bid. VMA, metanefrin and free cortisol levels were normalized one month after surgery. Blood glucose levels were

within normal levels on metformin 1000 mg bid, rosiglitazone 4 mg bid one month postoperatively and he had no hypertensive attacks. Two months after surgery his fasting blood glucose was 116 mg/ dl and his HbA1c was 6.2. (Table 2) The MRI studies of his pituitary and adrenal glands were completely normal 3 months later.

Discussion

An explanation for the occurrence of CS in some patients with PHEO was provided by the observation that PHEO can secrete an ACTH like polypeptide which induces bilateral adrenocortical hyperplasia and hyperfunction, thus causing “ectopic ACTH syndrome”.⁹ PHEO and CS may sometimes coexist and, very rarely, originate from the same adrenal gland. There have been 12 cases in the literature, in which corticomedullary involvement has been reported.^{6,7} In our case, PHEO and cortical hyperplasia coexisted in the same adrenal gland. The patient

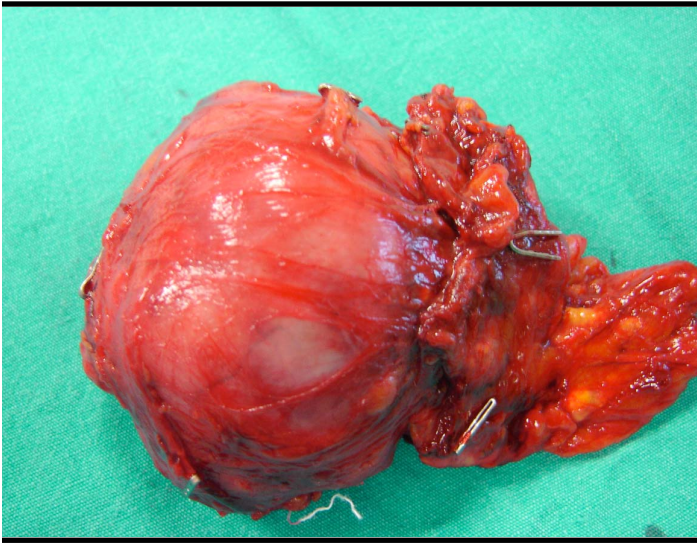


FIGURE 3. Right adrenal mass (surgical specimen).

was asymptomatic as far as PHEO or CS, in contrast to the 12 cases in the literature, most of which had symptoms related to either PHEO or CS. In addition, our case had normal blood pressure throughout. Up to 13% of the patients present with persistently normal blood pressure due to the catecholamine secretion; receptor down regulation because of consistently high levels of catecholamines; hypovolemia; and associated changes in sympathetic nerve function. Most phaeochromocytomas produce excess norepinephrine causing hypertension, some produce epinephrine causing

hypotension, and about 13% produce both, the balance of which determines the blood pressure.¹⁰ Insulin requirement was almost 200 IU per day preoperatively. One week after surgery blood sugar was controlled with metformin and rosiglitazone. This suggests that metabolic disorders with insulin resistance should be kept in mind, even if there is no clinical evidence, in patients who need large doses of insulin for blood glucose control.

In our patient, a high-dose 8-mg DEX suppression test using 24-hour urine cortisol showed more than 50% suppression, indicating a pituitary cause of CS with 90% sensitivity and 79% specificity, MRI investigation of the sella turcica revealed a pituitary microadenoma (4mm in diameter) on the right side of the adenohypophysis. Since the high-dose 8-mg DEX suppression test did not show more than 90% suppression, it indicates either a primary adrenal or ectopic ACTH cause of CS. Alternatively, this suggests the possibility of a pituitary cause with more sensitivity and specificity, if it showed more than 90% suppression. There was no bilateral adrenal hyperplasia on imaging which raises the possibility of the pituitary as a cause of CS. Thus, the 8 mg dex suppression test would have pointed out the possibility of the pituitary cause. The absence of bilateral adrenal hyperplasia on

TABLE 2. Postoperative laboratory parameters.

Biochemical parameters (plasma)		Hormone levels (normal values)			
Fasting blood glucose (mg/dL)	116	DHEA-S (µg/dL)	33 (35-430)	1 mg dex suppression (µg/dL)	1.62
Total cholesterol(mg/dL)	197	ACTH (pg/ml)	63 (0-46)	24 hour free cortisol in the urine (mcg/d)	28 (10-100)
Triglyceride (mg/dL)	231	Cortisol (µg/dL)	18.9 (5-25)	metanefrin (mcg/d)	73.1 (52-341)
LDL Cholesterol(mg/dL)	116	FSH (mIU/mL)	4.63 (1.5-12.4)	VMA (mg/d)	7.4 (3-9)
AST (IU/L)	18	LH (mIU/mL)	4.21 (1.7-8.6)		
ALT (IU/L)	23	Testosterone (ng/dl)	341 (181-758)		
BUN (mg/dL)	17	IGF-1 (ng/mL)	58.9 (71-290)		
Creatinine (mg/dL)	0.7	TSH mIU/mL)	1.35 (0.7-4.2)		
PTH (pg/mL)	133	Ft4 (ng/dl)	1.27		
Vit D (ng/mL)	<7	HbA1C	6.2		

ACTH: adrenocorticotrophic hormone
AST: aspartate aminotransferase
ALT: alanine aminotransferase
BUN: blood urea nitrogen
DHEA-S: dehydroepiandrosterone sulphate
FSH: follicle stimulating hormone

Ft4: free thyroxine
IGF-1: insulin like growth factor
LH : luteinizing hormone
PTH: parathyroid hormone
TSH: thyroid stimulating hormone

imaging ruled out CD or ectopic ACTH. One month after right adrenalectomy cortisol metabolism was normal and, therefore, we considered that the hypophysial adenoma was incidental. If the cause had been pituitary from the outset, cortisol metabolism would not be normal one month after adrenalectomy. Also, MRI study of the pituitary gland seven months after the operation was normal. This suggests that the preoperative MRI report was over-read.

Autonomous glucocorticoid production without specific signs and symptoms of Cushing's syndrome is termed pre clinical Cushing's syndrome. With an estimated prevalence of 79 cases per 100,000 persons, subclinical Cushing's syndrome is much more common than classic Cushing's syndrome. Patients with subclinical Cushing's syndrome lack the classical stigmata of hypercortisolism but have a high prevalence of obesity, hypertension, and type 2 diabetes.¹¹ PCS exhibits only lack of dex suppression and occasionally increased urinary cortisol excretion.¹² Morioka et al reported seven Japanese cases of PCS and observed that the most frequently found biochemical parameters of autonomous cortisol secretion were a low adrenocorticotropic hormone (ACTH) level (100%) and insufficient suppression of cortisol by low-dose dexamethasone (85.7%).¹³ Our case fulfilled the two required criteria, incidental adrenal mass associated with autonomous cortisol overproduction and lack of clinical characteristics of CS. We therefore diagnosed this case as PCS.

A critical issue is whether preclinical Cushing's syndrome may predispose to diseases such as arterial hypertension, obesity, or diabetes that are classical features of endogenous hypercortisolism and cluster in the metabolic syndrome. This is biologically plausible since many patients with clinically inapparent adrenal adenoma can be exposed to a chronic, albeit slight, cortisol excess. There are data indicating that some patients with subtle glucocorticoid excess may develop metabolic derangements, including insulin resistance, that may predispose to atherosclerosis and relevant cardiovascular complications. Interestingly, al-

terations in glucose metabolism and reduced insulin sensitivity are not restricted to patients with preclinical Cushing's syndrome. However, they are more marked in such patients than in those harboring non-functioning adenoma. An alternative hypothesis that adrenal incidentaloma may itself be an unrecognized manifestation of the metabolic syndrome could not be ruled out. A causal link between preclinical Cushing's syndrome and insulin resistance is the most plausible explanation for the available data.¹⁴

Conclusion

PHEO and cortical hyperplasia rarely coexist in the same adrenal gland. Cases in the literature had clinical features of either PHEO or CS. In our patient, we found an adrenal mass incidentally and the case is a rare report of PHEO combined with PCS in the same adrenal gland. It is important to investigate cortisol metabolism in patients with PHEO to diagnose concurrent clinical / subclinical CS. In the differential diagnosis of Cushing Syndrome, laboratory data and imaging studies might not always point towards a correct diagnosis. It is important to keep in mind that false positive results of tests and studies may complicate the clinical presentation.

References

1. Luton JP, Thieblot PH, Bricaire H. Association syndrome de Cushing-pheochromocytome. *Nouvelle Presse-Medicale* 1977;6:4053-47.
2. Forman BH, Marban E, Kayne RD et al Ectopic ACTH syndrome due to pheochromocytoma: case report and review of the literature. *Yale Journal of Biology and Medicine* 1979; 52: 181-189.
3. Crowell WT, Grizzle WE, Siegel AL. Functional carotid paragangliomas: biochemical, ultrastructural, and histochemical correlation with clinical symptoms. *Arch Pathol Lab Med* 1982;106:599-603.
4. Amos AM, McRoberts JW. Cushing's syndrome associated with a pheochromocytoma. *Urology*. 1998;52:331-5.
5. White A, Ray DW, Talbot A, Abraham P, Thody AJ, Bevan JS. Cushing's syndrome due to pheochromocytoma.

- cytoma secreting the precursors of adrenocorticotropin. *J Clin Endocrinol Metab.* 2000;85:4771-5.
6. Erem C, Hacıhasanoğlu A, Ersoz HO et al. Pheochromocytoma combined with pre-clinical Cushing's syndrome in the same adrenal gland. *J Endocrinol Invest.* 2005;28:561-5.
 7. Finkenstedt G, Gasser RW, Hofle G et al Pheochromocytoma and sub-clinical Cushing's syndrome during pregnancy: diagnosis, medical pre-treatment and cure by laparoscopic unilateral adrenalectomy. *J Endocrinol Invest.* 1999;22:551-7.
 8. Terzolo M, Reimondo G, Bovio S, Angeli A. Sub-clinical Cushing's syndrome. *Pituitary* 2004;7:217-23.
 9. Hartmann CA, Gross U, Stein H. Cushing syndrome-associated pheochromocytoma and adrenal carcinoma. An immunohistological investigation. *Pathol Res Pract.* 1992;188:287-95.
 10. Bravo EL, Tarazi RC, Fouad FM et al: Clonidine suppression test: A useful aid in the diagnosis of pheochromocytoma. *N Engl J Med* 1981;305:623-6.
 11. Reincke M. Subclinical Cushing's syndrome. *Endocrinol Metab Clin North Am.* 2000;29: 43-56
 12. Reincke M, Nieke J, Krestin GP, Saeger W, Allolio B, Winkelmann W. Preclinical Cushing's syndrome in adrenal "incidentalomas": comparison with adrenal Cushing's syndrome. *J Clin Endocrinol Metab.* 1992;75:826-32.
 13. Morioka M, Fujii T, Matsuki T, et al . Preclinical Cushing's syndrome: report of seven cases and a review of the literature. *Int J Urol.* 2000;7:126-32.
 14. Terzolo M, Reimondo G, Bovio S, Angeli A. Sub-clinical Cushing's syndrome. *Pituitary.* 2004;7:217-23.

Correspondence to:

Guzin Fidan Yaylali, MD
 Pamukkale University, School of Medicine
 Department of Endocrinology and Metabolic Diseases
 Kınıklı kampusu 20070 Kinikli, Denizli, Turkey
 E-mail: guzinf@gmail.com